

Title page

Title: A randomised control trial evaluating fluorescent ink versus dark ink tattoos for breast radiotherapy

Short title: Invisible tattoos for Breast Radiotherapy

Full manuscript

Steven J Landeg BSc (Hon) MSc ², Anna M Kirby MD^{1,2}, Steven F Lee DPhil³, Freddie Bartlett MD^{1,2,5}, Kumud Titmarsh MA⁴, Ellen Donovan PhD², Clare L Griffin MSc¹, Lone Gothard HND¹ Imogen Locke MD², Helen A McNair DCR(T) PhD^{1,2}

- (1) The Institute of Cancer Research (ICR), London
- (2) The Royal Marsden NHS Foundation Trust, London
- (3) Department of Chemistry, University of Cambridge, Cambridge
- (4) Kingston University, London
- (5) Southampton Oncology Centre, Southampton University Hospitals, Southampton

Corresponding author: Steven J Landeg, The Royal Marsden, Downs Road, Sutton SM2 5PT. Email: steven.landeg@rmh.nhs.uk. Tel: 020 8915 6774

Acknowledgements

This work was supported by The Institute of Cancer Research (ICR), and Cancer Research UK grant numbers C46/A3970 and C33589/A19727 to the ICR Section of Radiotherapy. We acknowledge NHS funding to the National Institute for Health Research (NIHR) Biomedical Research Centre at The Royal Marsden and the ICR. Ellen Donovan is supported by the National Institute for Health Research via a Career Development Fellowship (CDF-2013-06-005). We would like to thank the Royal Society for the University Research Fellowship of Steven Frank Lee (UF120277).

The views expressed in this publication are those of the author(s) and not necessarily those of the NHS, the National Institute for Health Research or the Department of Health. We are grateful to all the patients and radiographers for their invaluable support in allowing this research to be realised.

1
2
3
4
5
6
7
8
9
10
11
12
13
14
15
16
17
18
19
20
21
22
23
24
25
26
27
28
29
30
31
32
33
34
35
36
37
38
39
40
41
42
43
44
45
46
47
48
49
50
51
52
53
54
55
56
57
58
59
60
61
62
63
64
65

Abstract

Objectives

The purpose of this UK study was to evaluate inter-fraction reproducibility and body image score when using Ultraviolet (UV) tattoos (not visible in ambient lighting) for external references during breast/chest wall radiotherapy and compare to conventional dark ink.

Methods

In this non-blinded, single centre, parallel group, randomised control trial, patients were allocated 1:1 to receive either conventional dark ink or UV ink tattoos using computer generated random blocks. Participant assignment was not masked. Systematic (Σ) and random (σ) set-up errors were determined using electronic portal images (EPI). Body image questionnaires were completed at pre-treatment, one month and six months to determine the impact of tattoo type on body image. The primary end point was to determine that UV tattoo random error (σ_{setup}) was no less accurate than with conventional dark ink tattoos, i.e. < than 2.8 mm.

Results

Forty six patients were randomised to receive conventional dark or UV ink tattoos. 45 patients completed treatment (UV: n = 23, Dark: n = 22). σ_{setup} for the UV tattoo group were less than 2.8 mm in the u and v directions (p 0.001; p 0.009 respectively). A larger proportion of patients reported improvement in body image score in the UV tattoo group compared to

1
2
3
4
5
6
7
8
9
10
11
12
13
14
15
16
17
18
19
20
21
22
23
24
25
26
27
28
29
30
31
32
33
34
35
36
37
38
39
40
41
42
43
44
45
46
47
48
49
50
51
52
53
54
55
56
57
58
59
60
61
62
63
64
65

the dark ink group at one month (56% (13/23) vs 14% (3/22) respectively) and six months (52%(11/21) vs. 38% (8/21) respectively).

Conclusions

UV tattoos were associated with comparable inter-fraction setup reproducibility to conventional dark ink. Patients reported more favorable change in body image score up to six months following treatment.

Advances in knowledge

This study is the first to evaluate UV tattoo external references in a randomised control trial.

Introduction

The number of breast cancer (BC) survivors is rising with most recent estimates suggesting there are over 500,000 such women in the UK alone (1). Consequently, an acceptable cosmetic outcome following treatment is of importance to women in this increasing population (2).

Dark ink tattoos (1-3 mm diameter) are routinely used in the majority of radiotherapy (RT) departments to reproduce the patient's planned position and ensure precise radiation delivery (3). Furthermore, the use of external references, immobilisation and image guidance in modern radiotherapy practice mitigate the risk of geographic miss, ensuring compliance with ICRU 50 guidelines (4). The Royal College of Radiologists (RCR) cite a survey by Dobbs et al. (2003) suggesting systematic (Σ_{setup}) and random errors (σ_{setup}) of 3.2 mm and 2.9 mm respectively for breast radiotherapy (5).

Despite the clear advantages of dark ink RT tattoos, they are associated with the following limitations:

- a) It has been reported that 15-30% of BC patients experience body image concerns that persist into survivorship (6) and a number of other authors have suggested that RT tattoos may contribute to body image dissatisfaction (2, 6-8). Changes to physical appearance and body function are associated with poorer psychosocial outcomes including anxiety and depression (8, 9). A UK survey of RT departments suggested that breast radiotherapy patients do not want a permanent reminder of

1
2
3
4 treatment and are most likely to decline permanent tattoos for cosmetic reasons
5
6 (Townend 2014, national audit results, unpublished);
7
8
9

10
11 b) melanocytic lesions or hair follicles can be mistaken for tattoos potentially causing
12 errors in treatment delivery (7, 10);
13
14

15
16
17
18 c) religious or cultural beliefs may prohibit or make patients feel uncomfortable about
19 receiving tattoos (7);
20
21
22

23
24
25
26 d) It has also been reported that dark ink tattoos can be difficult to localise when
27 patients have dark skin tone (7).
28
29
30

31
32
33 Alternatives to dark ink tattoos include semi-permanent marking methods, however these
34 have been found to be inferior to dark ink tattoos in terms of patient comfort, durability and
35 longevity (2, 11). In this study we test the use of 'UV ink' tattoos. This ink is a light-coloured
36 tattoo pigment combined with an ultraviolet (UV) responsive fluorescent dye. This ink is
37 observable under UV light when the wavelength of emission from the fluorophore is Stokes'
38 shifted into the visible region of the electromagnetic spectrum. However, once the excitation
39 source is removed, the dye does not fluoresce and therefore the tattoo becomes 'invisible' in
40 ambient lighting.
41
42
43
44
45
46
47
48
49
50

51
52
53
54
55 In this study we focus on a commercially available tattoo ink whose active component is the
56 non-toxic fluorescent compound 7-diethylamino-4-methylcoumarin (Coumarin 1) dispersed in
57 a Melamine formaldehyde toluenesulfonamide polymer matrix (Figure 1A). It was found that
58
59
60
61
62
63
64
65

1
2
3
4 the ink had an excitation maximum of ~390 nm (Figure 1B – dashed) and a peak emission at
5
6 ~435 nm (Figure 1B – red). This light is readily observed as a blue/green fluorescence
7
8 (Figure 1C). Excitation is facilitated by the use of a handheld wavelength-matched UV torch
9
10 with a peak emission of 375 nm (\pm 5 nm, FWHM). Further spectral filtering was not required
11
12 to directly visualise the tattoo on the skin surface.
13
14

15
16
17
18
19 Several preliminary investigations using chicken and pig skin suggest that UV ink tattoos
20
21 may offer superior radiotherapy marking compared to conventional dark ink (7, 10).
22

23
24 However, further investigation with human subjects has been recommended. A dermatology
25
26 study proposed that UV ink tattoos could be used as a discrete method to aid the correct
27
28 identification of cutaneous biopsy sites (12). This single patient study indicated that UV ink
29
30 may have sufficient longevity to provide a record of RT throughout the patient's life, although
31
32 this has not been verified, and may be dependent on a number of variables such as UV
33
34 exposure (13).
35
36
37
38
39

40
41 These studies indicate that UV ink tattoos offer a viable alternative to dark ink. Additionally,
42
43 they may ameliorate body image dissatisfaction and improve the patient's experience of
44
45 breast radiotherapy. Indeed, a patient-advocate group who were consulted about the
46
47 patient's experience of RT tattoos confirmed that the negative experience may impact upon
48
49 survivorship for some women. This study investigated the use of UV ink in the radiotherapy
50
51 treatment of breast cancer. The primary aim was to evaluate inter-fraction reproducibility
52
53 using UV ink tattoos. Secondary aims were to assess body image satisfaction, radiographer
54
55 satisfaction, tattoo visibility in dark skin-tone, and the time burden at the treatment unit.
56
57
58
59
60
61
62
63
64
65

1
2
3
4
5
6
7 **Materials and Methods**
8
9

10
11 This study was approved by The Royal Marsden Committee for Clinical Research and a
12 NHS Research Ethics Committee. All women had undergone breast conserving surgery or
13 mastectomy for early stage invasive ductal or lobular carcinoma (pT1-3b N0-1 M0) and had
14 been recommended adjuvant radiotherapy to the whole breast or chest wall (with or without
15 nodal irradiation or tumour bed boost). Dose prescription was 40 Gray (Gy) in 15 fractions
16 (+/-13.35 Gy/5 tumour bed boost) over 3-4 weeks.
17
18
19
20
21
22
23
24
25
26
27

28 The absorption and emission characteristics of two UV tattooing ink products were
29 determined using a Cary Eclipse Fluorescence Spectrophotometer (Agilent Technologies,
30 CA) (Figure 1). A selection of UV torches were also tested to determine peak emission
31 wavelengths using a compact CCD spectrometer (Thorlabs, CCS175). This analysis
32 revealed that the selected dye (Nuclear Fallout, Millenium colorworks, CA) is well suited to
33 the light emitted by the UV torch (INOVA X5, Nite Ize Inc. Boulder), and the primary emission
34 wavelength of the dye is in the visible region of the electromagnetic spectrum. Consultation
35 with a professional tattoo artist demonstrated that round liner (size 3) professional tattooist
36 needles were the most effective for manually administering UV ink into the dermis. The UV
37 ink was available in 1 oz bottles and decanted into sterile receptacles for each patient before
38 administration with sterile lance.
39
40
41
42
43
44
45
46
47
48
49
50
51
52
53
54
55
56

57 All radiographers were trained in safe and accurate operation of UV handheld torches,
58 adhering to International Commission for Non-ionising Radiation protection (ICNIRP) 2004
59
60
61
62
63
64
65

1
2
3
4 (14). UV torch emission was measured to ensure exposure limit values (ELV) for skin and
5
6 eyes would not be exceeded for patient or user during clinical use (ELVs defined by ICNIRP
7
8 2004) (16). Pre-treatment radiographers were trained in the safe and effective administration
9
10 of UV ink tattoos.
11
12
13
14

15
16 All patients were positioned on a breast board (Medtec, Indiana) and CT scan images were
17
18 acquired using 3 mm slice thickness/spacing. Tattoos were marked bilaterally and medially
19
20 with the addition of an anterior supra-clavicular tattoo if required. A hypodermic needle was
21
22 used to administer dark ink tattoos as per standard departmental practice. Measurements
23
24 from anatomic landmarks and photographs were taken to record the location of UV tattoos.
25
26 The handheld UV torch was used during treatment sessions to locate and mark (using a fine
27
28 marker pen) the centre of UV tattoos to facilitate daily-setup.
29
30
31
32
33

34
35 The primary endpoint was inter-fraction reproducibility measured using EPI images acquired
36
37 from the tangential treatment fields, for fractions 1 to 3, and a minimum of once weekly
38
39 thereafter. Template matching was used to register chest wall and contour as visualised on
40
41 EPI's with digitally reconstructed radiographs (DRR) to quantify displacements from planned
42
43 position. Displacements were recorded in the u - v plane in mm (Figure 2).
44
45
46
47
48
49

50
51 Secondary endpoints included patient body image, radiographer satisfaction, time taken at
52
53 CT simulation and treatment delivery, and ease of visualisation of UV tattoos in patients with
54
55 darker skin tone. The influence of tattoo type on body image was measured using a ten item
56
57 validated body image scale (BIS) (Appendix A). Patients were asked to complete
58
59 questionnaires at baseline (before the radiotherapy planning CT scan), and at one and six
60
61
62
63
64
65

1
2
3
4 months post CT simulation. Opportunity for verbatim responses was also provided.
5
6 Radiographers were asked to complete satisfaction questionnaires at CT simulation and
7
8 once weekly during treatment. Questions related to ease of administration and visualisation
9
10 of tattoos. All questions had a response on a scale of 0 to 3 with space for comments
11
12 (Appendix B). The time on and off CT or treatment couch was recorded as well as beam on
13
14 and off time.
15
16
17
18
19
20

21 A Felix von Luschan chromatic scale was modified and used by CT simulation radiographers
22
23 to record patient skin-tone (Appendix C). The scale was simplified into three distinct groups
24
25 (White European [1], East Asian [2] and Sub Saharan skin tone [3]).
26
27
28
29
30
31
32

33 **Statistical considerations**

34
35
36
37

38 To rule out σ_{setup} of greater than 2.8 mm when using UV tattoos, assuming a σ_{error} of 2 mm
39
40 with dark ink tattoos and a standard deviation of 1.0 mm, required 21 patients in each group
41
42 (42 in total) based on a two sample t-test with 80% power and a 1-sided 5% significance
43
44 level.
45
46
47
48
49

50 Patients were randomised using a 1:1 ratio by a telephone call to the local clinical trials and
51
52 statistics unit (ICR-CTSU). Computer generated random blocks were used and allocation
53
54 was non-blinded.
55
56
57
58
59
60
61
62
63
64
65

1
2
3
4 Statistical analyses were performed using SPSS Statistics Version 19 (IBM, Portsmouth,
5 UK). EPI displacements were quantified for anterior and posterior oblique beams. These
6
7 displacements were averaged to determine daily errors in u and v directions for each imaged
8
9 session. The RCR (2008) (15) guidelines were used to calculate individual and population
10
11 random (σ_{setup} σ_{error}) and systematic (\sum_{setup} , \sum_{error}) errors in both directions. Descriptive
12
13 statistics were reported and formal statistical comparisons between groups were made using
14
15 t-tests. A one sided, one-sample t-test was used to determine whether σ_{setup} errors
16
17 calculated for the UV tattoo group were less than 2.8 mm in both u and v directions.
18
19
20
21
22
23
24
25

26 The changes in BIS from baseline to one month and baseline to six months were computed
27
28 and compared between groups using a Mann-Whitney U test. Changes from baseline at
29
30 each time point were also categorised as no change, improvement or worsening of score.
31
32 Participant's verbatim responses were analysed and salient themes reported.
33
34
35
36
37

38 Radiographer satisfaction scores were calculated and compared between conditions for CT
39
40 simulation and treatment stages using descriptive statistics and Mann-Whitney analysis.
41
42 Scores ranged from 0 (no satisfaction) to 9 (complete satisfaction). Verbatim responses were
43
44 analysed and comments representing salient themes reported.
45
46
47
48
49

50 Total session times and treatment setup durations were reported using descriptive statistics
51
52 and Mann Whitney U test for comparison.
53
54
55
56

57 Analyses were conducted on an intention to treat basis once the last patient had reached the
58
59 six month follow-up.
60
61
62
63
64
65

Results

Forty-six patients (23 dark ink, 23 UV ink) were randomised from a single UK centre between April 2014 and July 2014. The median age of participants was 57 years (range: 30-70) and the majority of patients were white European (Table 1). There were no significant differences in baseline characteristics between the two groups.

One patient was consented and randomised to the dark ink group but did not commence treatment due to a change in clinical management. Forty-five patients completed RT. All patients treated within the study have now been followed up for two years and there have been no reports of tattoos becoming visible in ambient lighting or any tattoo-related skin toxicity for either group.

Random setup error (σ_{setup}) for patients receiving UV tattoos measured in the u and v directions were statistically less than the pre-specified 2.8 mm (p. 0.001; p. 0.009 respectively). No statistically significant differences between groups were found in σ and Σ errors in any direction (Table 2).

One hundred percent (45/45) and ninety-six percent (43/45) of participants completed the body image questionnaires at one month and six months respectively, post CT simulation.

Fifty-six percent (13/23) of patients with UV tattoos reported improved body image as compared to only 14% (3/22) of those with dark ink at one month compared to baseline.

Worsening body image score was reported by 22% (5/23) of patients with UV tattoos compared to 50% (11/22) with dark ink at one month compared to baseline. A similar

1
2
3
4 distribution was seen at the six-month stage with a worse score reported by 24% (6/23) and
5
6 48% (11/22) of patients respectively compared to baseline.
7
8
9

10
11 Median BIS were consistent for the UV tattoo group with a median score of 7 at both
12
13 baseline and one month. However, median BIS scores showed deterioration for the dark ink
14
15 group with scores of 5.5 and 6.5 at baseline and one month respectively. At six months
16
17 however, median scores had improved (decreased) from the baseline by 1.0 for the UV
18
19 group and 0.5 for the dark ink group. No statistical difference in score change was found
20
21 between groups. Comments suggested that some patients had concerns about the visibility
22
23 of dark ink reference marks as shown below.
24
25
26
27
28
29

30
31 *"I feel much better without tattoos being visible. Much more confident"*

32
33 (patient comment UV ink group)
34
35
36
37

38 Some participants may associate visibility of dark ink tattoos with cosmetic concerns or
39
40 negative feelings as illustrated below,
41
42
43
44

45 *"I don't really have a problem with the tattoos but yes they do serve to remind you of a*
46
47 *particularly traumatising experience"* (patient comment dark ink group)
48
49
50

51
52
53 Median CT simulation time was 16 (IQR:8; Range: 9-45) vs. 20 minutes (IQR: 8; Range: 15-
54
55 35) for the dark and UV ink groups respectively. Median treatment setup time increased from
56
57 5 (IQR: 2; Range: 2-16) to 6 (IQR: 3; Range: 1-24) minutes for dark ink and UV ink
58
59 respectively. Total treatment session median times were increased from 9 (IQR: 5; Range: 4-
60
61
62
63
64
65

1
2
3
4 48) to 10 (IQR: 5; Range: 4-48) minutes for dark and UV ink respectively (Table 3).

5
6 Differences in CT simulation, setup and total treatment times were found to be statistically
7
8 significant.

9
10
11
12
13
14 Median radiographer satisfaction scores (RSS) were lower when using UV tattoos compared
15
16 with dark ink at CT simulation and week two time points (8 vs 9 respectively). Median scores
17
18 were equivalent for week one and three (9 vs 9 respectively) but the range in RSS was
19
20 greater for UV tattoos (Figure 3). Lower scores observed for the UV tattoo group were found
21
22 to be statistically significant for all stages of the treatment pathway except week one.
23
24

25
26
27
28 Radiographer UV tattoo comments (CT simulation n=12; Treatment n=28) revealed that
29
30 difficulty in administering tattoos and poor visibility on some patient's skin were likely
31
32 responsible for reduced satisfaction. Radiographers were not able to locate all UV tattoos in
33
34 both patients with Sub Saharan skin tone (Category 3 skin tone). These patients were re-
35
36 tattooed with standard dark ink, however, one comment suggested there was further
37
38 difficulty locating the dark ink tattoos for one of these participants and the anterior UV tattoo
39
40 was still used for setup.
41
42
43
44
45
46
47
48
49

50 **Discussion**

51
52
53
54
55 This study has shown that setup accuracy using UV ink tattoos is comparable to that using
56
57 standard dark ink. Moreover, the use of UV ink is associated with more favourable change in
58
59 patients' body image score compared to conventional dark ink.
60
61
62
63
64
65

1
2
3
4
5
6
7
8
9
10
11
12
13
14
15
16
17
18
19
20
21
22
23
24
25
26
27
28
29
30
31
32
33
34
35
36
37
38
39
40
41
42
43
44
45
46
47
48
49
50
51
52
53
54
55
56
57
58
59
60
61
62
63
64
65

The study sample captured a broad age range of female patients and was representative of a South-West London population. The absence of any reported tattoo ink skin reactions was consistent with other authors' assertions (7, 16). Furthermore, this finding implies there is great potential for the clinical use of UV ink in radiotherapy treatment set-ups.

Set-up accuracy data indicates that UV tattoos are associated with clinically acceptable inter-fraction reproducibility and therefore may be used as an alternative to dark ink tattoos.

The lack of a statistically significant difference between set-up with the two marking methods is reassuring although the study was not powered to detect small differences in σ_{error} and \sum_{error} between the two groups. Overall, UV tattoo setup accuracy was within RCR (2008) recommendations (<3 mm) (15).

BIS comparison can only be made between the time points captured, as many variables known to influence body image could not be controlled for in this small sample e.g. type of surgery (17, 18), however, baseline characteristics showed no significant differences between the groups. Some authors found that body image is sensitive to time since surgery (17), and so BIS cannot be solely attributable to tattoo type, however, differences in the direction or degree of change between groups may indicate an effect.

Results suggest that invisible tattoos have a less negative impact on body image compared to dark ink. However, such a large difference between the groups is perhaps unexpected and could be the result of anticipation bias *i.e.* as the study was non-blinded, patients may

1
2
3
4 have been influenced by their randomisation, with UV tattoo patients scoring more
5
6 favourably compared to the dark ink group.
7
8
9

10
11 It is difficult to know whether such differences between the groups are a result of tattoo type,
12
13 bias or other variables that could not be controlled for. However, comments suggest that a
14
15 proportion of patients value having invisible markings.
16
17
18
19
20

21 By offering UV tattoos departments are likely to improve the patient's experience of breast
22
23 RT by offering choice and addressing the cosmetic and psychological concerns associated
24
25 with conventional dark ink tattoos.
26
27
28
29
30

31 Radiographers reported greater satisfaction using conventional dark ink tattoos. Comments
32
33 indicated that difficulty in administering and increased time to locate UV tattoos were partly
34
35 responsible. Comments suggested that radiographer training and exposure to this new
36
37 tattooing technique is important to deliver consistent, viable markings. Despite lower
38
39 radiographer satisfaction, UV tattoos were visible in all participants except those with Sub
40
41 Saharan skin tone (91% n = 21/23). However, because of the small number of patients with
42
43 category 3 skin tone recruited (n = 2) it is not possible to comment on the role of UV tattoos
44
45 to enhance visibility in patients with darker skin tone and further investigation is required.
46
47
48
49
50

51
52
53 Timing analysis suggested there was an increase in CT simulation time. This is likely
54
55 attributable to time spent measuring and documenting UV tattoo location and taking
56
57 additional photos. Set-up time and overall treatment time were also marginally increased in
58
59 the UV tattoo group. This could be partly accounted for by the need to use a UV light source
60
61
62
63
64
65

1
2
3
4 to highlight markings which constitutes an additional task within the workflow. Difficulty
5
6 visualising tattoos in some participants may also contribute to the protracted setup and
7
8 treatment times recorded.
9

10
11
12
13
14 UV tattoos offer clinically acceptable inter-fraction reproducibility compared to conventional
15
16 dark ink when used to setup patients with white European and East Asian skin tones. A
17
18 difference in change of BIS between the two groups suggests improved satisfaction with UV
19
20 tattoos. Patient comments further support the hypothesis that a significant proportion of
21
22 women are likely to derive benefit from not having dark ink radiotherapy markings.
23
24
25
26
27
28
29

30 31 **Conclusion** 32 33 34

35
36 UV tattoos offer comparable set-up accuracy to that of conventional dark ink and may
37
38 improve patient experience of breast radiotherapy. UV tattoos are also associated with an
39
40 improvement in BIS compared to standard dark ink.
41
42
43
44

45 **Conflict of Interest:** None declared.
46
47
48
49
50
51
52
53
54
55
56
57
58
59
60
61
62
63
64
65

1
2
3
4
5
6
7
8
9
10
11
12
13
14
15
16
17
18
19
20
21
22
23
24
25
26
27
28
29
30
31
32
33
34
35
36
37
38
39
40
41
42
43
44
45
46
47
48
49
50
51
52
53
54
55
56
57
58
59
60
61
62
63
64
65

Figure 1 Principle of invisible tattoos; (A) Wide-field fluorescence micrograph of a 10^6 dilution of tattoo ink in PBS (excited with 405 nm light) demonstrating dye molecule dispersed in polymer. Scale bar is 3 μm (B) Spectral properties of UV tattoo ink; Excitation (Exc.) [dashed red] and emission (Em.) [solid red] spectra of the UV ink and the emission spectrum of the handheld torch used to visualise the dye [Blue] (C) Manufactured sample skin tattooed with standard dark (left) and UV ink (right) under ambient (top) and UV light (bottom). UV is invisible under ambient light and clearly visible under UV illumination with a handheld UV torch. Scale Bar is 25 mm.

Figure 2 Right anterior oblique (RAO) tangential field digitally reconstructed radiographer (DRR) to illustrate the u and v directions (arrows) in the imaging plane.

Figure 3 Radiographer satisfaction scores (RSS) for UV (Left) and Dark (Right) ink tattoos at CT simulation and each week of treatment.

References

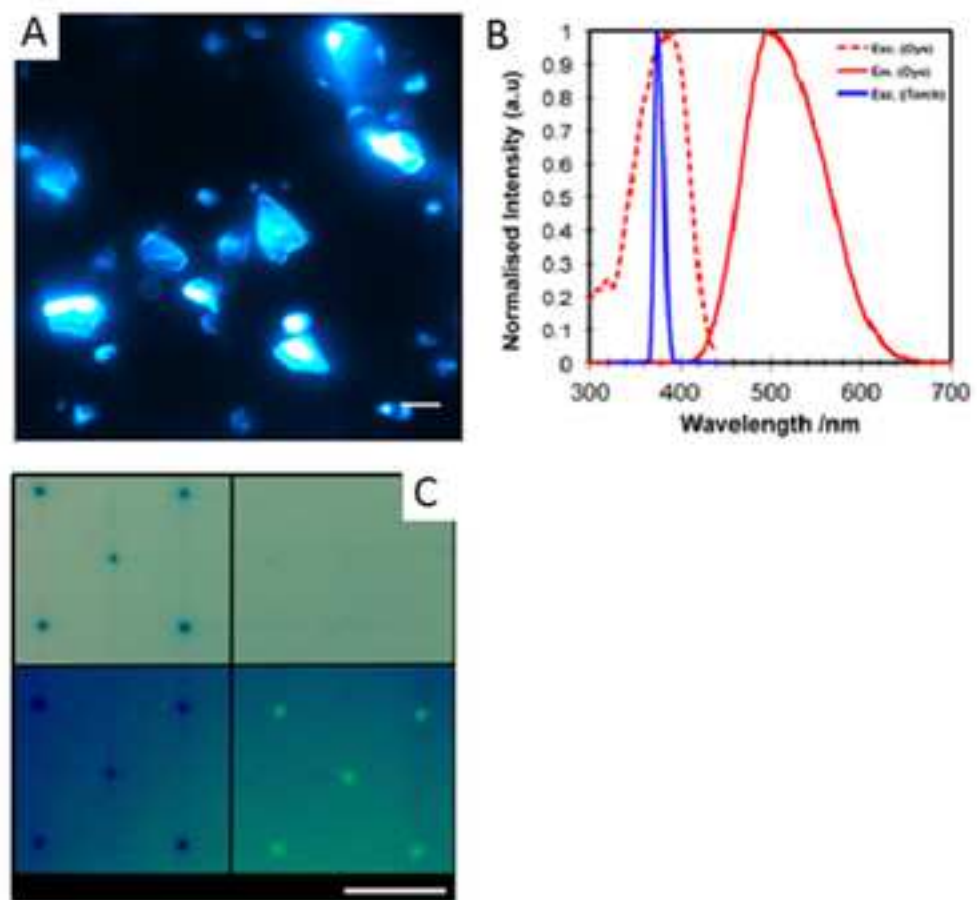
1. National cancer survivorship initiative (2013) Living with and beyond cancer: Taking action to improve outcomes. Available at: <http://www.ncsi.org.uk/wp-content/uploads/Living-with-and-beyond-2013.pdf> (Accessed 1 Dec 2014).
2. Probst H, Dodwell D, Gray JC, Holmes M. An evaluation of the accuracy of semi-permanent skin marks for breast cancer irradiation. *Radiography*. 2006;12:186-8.
3. Glassy CM, Glassy MS, Aldasouqi S. Tattooing: medical uses and problems. *Cleve Clin J Med*. 2012;79(11):761-70.
4. Landberg T, Chavaudra J, Dobbs J. 'Report No. 50: Prescribing, Recording, and Reporting Photon Beam Therapy'. Washington: International Commission of Radiation Units and Measurements. 1993.
5. Dobbs H, Greener AG, Driver DM. Geometric uncertainties in radiotherapy of the breast. In: *Geometric Uncertainties in Radiotherapy*. London.: The British Institute of Radiology; 2003. p. 47-76.
6. Fingeret MC, Teo I, Epner DE. Managing body image difficulties of adult cancer patients: lessons from available research. *Cancer*. 2014;120(5):633-41.
7. Smolenski MC. Tattooing method for radiation therapy, Available at: <Http://www.Google.pl/patents/WO2008074052A1?cl=en>. [Accessed: 10/11/2013]. 2008.
8. Fobair P, Stewart SL, Chang S, D'Onofrio C, Banks PJ, Bloom JR. Body image and sexual problems in young women with breast cancer. *Psychooncology*. 2006;15(7):579-94.
9. Bregnhøj A, Haedersdal M. Q-switched YAG laser vs. punch biopsy excision for iatrogenic radiation tattoo markers--a randomized controlled trial. *Journal of the European Academy of Dermatology and Venereology : JEADV*. 2010;24(10):1183-6.

- 1
2
3
4 10. David EJ, Castle SKB, Mossi KM. Localization Tattoos: An Alternative Method Using
5
6
7
8
9
10
11
12
13
14
15
16
17
18
19
20
21
22
23
24
25
26
27
28
29
30
31
32
33
34
35
36
37
38
39
40
41
42
43
44
45
46
47
48
49
50
51
52
53
54
55
56
57
58
59
60
61
62
63
64
65
10. David EJ, Castle SKB, Mossi KM. Localization Tattoos: An Alternative Method Using
Fluorescent Inks. *Radiation Therapist*. 2006;15(1):1-5.
11. Rafi M, Tunio MA, Hashmi AH, Ahmed Z. Comparison of three methods for skin
markings in conformal radiotherapy, temporary markers, and permanent Steritatt CIVCO®
tattooing: Patients' comfort and radiographers' satisfaction. *The South African Radiographer*.
2009;47(2):20-2.
12. Chuang GS, Gilchrest BA. Ultraviolet-fluorescent tattoo location of cutaneous biopsy
site. *Dermatologic surgery : official publication for American Society for Dermatologic
Surgery [et al]*. 2012;38(3):479-83.
13. Sperry K. Tattoos and tattooing. Part II: Gross pathology, histopathology, medical
complications, and applications. *The American journal of forensic medicine and pathology*.
1992;13(1):7-17.
14. International Commission on Non-Ionizing Radiation P. Guidelines on limits of
exposure to ultraviolet radiation of wavelengths between 180 nm and 400 nm (incoherent
optical radiation). *Health physics*. 2004;87(2):171-86.
15. RCR, On target: Ensuring geometric accuracy in radiotherapy. 2008 London: The
Royal College of Radiologists.
16. Kluger N. Ultraviolet-fluorescent tattoo for radiotherapy marking? *Dermatologic
surgery : official publication for American Society for Dermatologic Surgery [et al]*.
2012;38(6):966-7.
17. Hopwood P, Fletcher I, Lee A, Al Ghazal S. A body image scale for use with cancer
patients. *Eur J Cancer*. 2001;37(2):189-97.
18. Moreira H, Canavarro MC. A longitudinal study about the body image and
psychosocial adjustment of breast cancer patients during the course of the disease.

1
2
3
4
5
6
7
8
9
10
11
12
13
14
15
16
17
18
19
20
21
22
23
24
25
26
27
28
29
30
31
32
33
34
35
36
37
38
39
40
41
42
43
44
45
46
47
48
49
50
51
52
53
54
55
56
57
58
59
60
61
62
63
64
65

European journal of oncology nursing : the official journal of European Oncology Nursing
Society. 2010;14(4):263-70.

BJR UNCORRECTED PROOFS



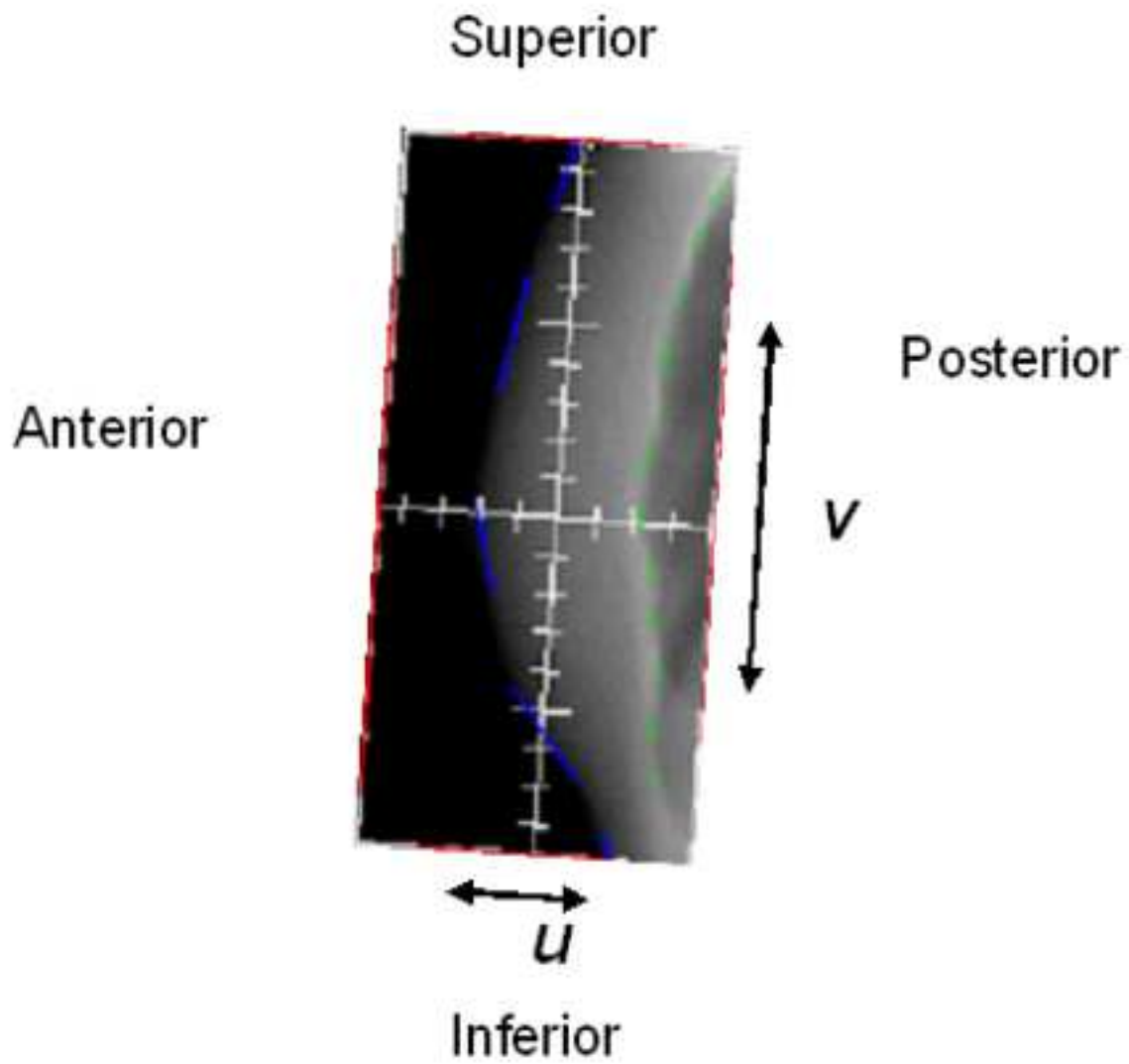


Figure 3

Radiographer satisfaction scores for UV (Left) and Dark (Right) ink tattoos.

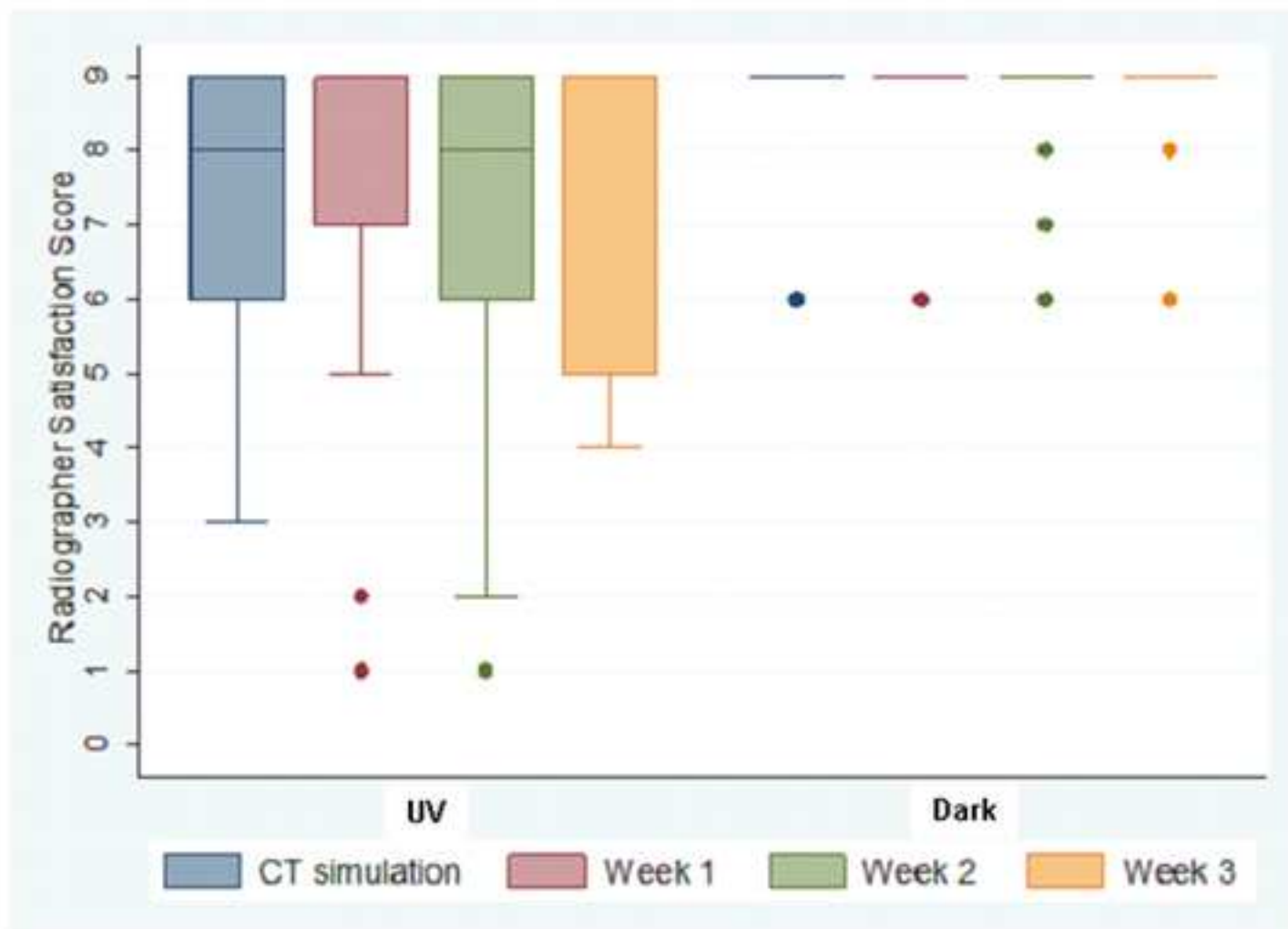


Table 1

Baseline characteristics for each group

		UV ink tattoos N=23 n (%)	Dark ink tattoos N=22 n (%)	P-value
Age	Mean (SD) range	58 (12.73) 30-79	56 (8.83) 43-71	0.618
Surgery	Breast conservation Mastectomy	19 (83) 4 (17)	20 (91) 2 (9)	0.413
Nodal irradiation	Yes No	3 (13) 20 (87)	1 (5) 21 (95)	0.317
Tumour bed boost	Yes No	4 (17) 19 (83)	8 (36) 14 (64)	0.150
Chemotherapy received	Yes No	6 (26) 17 (74)	4 (18) 18 (82)	0.524
Skin tone	White European	16 (70)	13 (59) ¹	0.261
	East Asian	5 (22)	5 (23)	
	Sub-Saharan	2 (9)	4 (18)	

NB. Statistical comparisons have been made using the t-test for age, chi-square test for trend for skin tone, and chi-square tests for all other baseline characteristics.

¹Baseline data was not available for the patient who did not receive RT.

Table 2

Setup accuracy data (mm) in u and v directions (mm)

Direction		UV ink group	Dark ink group	Sig. (2-tailed)
v	MD	-0.3	-0.3	-
	Σ	1.5	1.1	0.865
	σ	2.1	1.5	0.068
u	MD	-0.3	-0.8	-
	Σ	2.0	1.7	.337
	σ	2.0	1.8	0.469

MD : Population mean displacement,

 Σ : Population systematic error σ : Population random error

Table 3

Timing data (minutes)

		Ink Type		
		Dark	UV	Mann Whitney p-values
CT simulation	Median	16	20	.0203
	Q1	14	17	
	Q3	22	25	
	Min	9	15	
	Max	45	35	
Treatment Setup time	Median	5	6	<.0001
	Q1	4	5	
	Q3	6	8	
	Min	2	1	
	Max	16	24	
Treatment Total time	Median	9	10	.0138
	Q1	7	8	
	Q3	12	13	
	Min	4	4	
	Max	48	48	



Click here to access/download
Supplementary material
Supplementary material.pdf